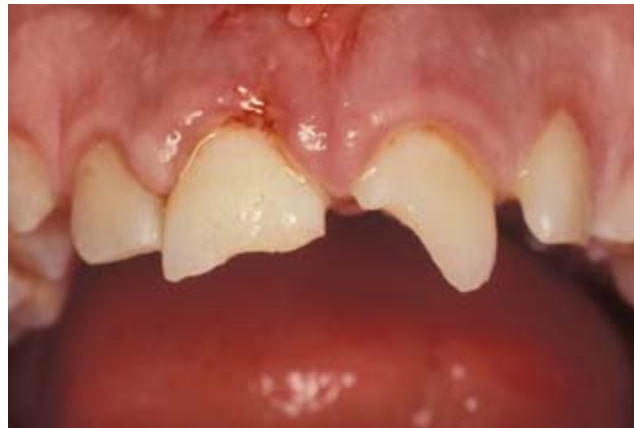



International Association of Dental Traumatology

DENTAL TRAUMA GUIDELINES

Revised 2011



CONTENT:

Section 1. Fractures and luxations of permanent teeth

Section 2. Avulsion of permanent teeth

Section 3. Traumatic injuries to primary teeth

Disclaimer: These guidelines are intended to provide information for health care providers caring for patients with dental injuries. They represent the current best evidence based on literature research and professional opinion. As is true for all guidelines, the health care provider must apply clinical judgment dictated by the conditions present in the given traumatic situation. The IADT does not guarantee favorable outcomes from following the Guidelines, but using the recommended procedures can maximize the chances of success.

These Guidelines have been endorsed by the following professional organizations: **(We will add organizations as they provide their endorsements)**

INTRODUCTION

Traumatic dental injuries (TDIs) occur with great frequency in preschool, school age children and young adults comprising 5% of all injuries for which people seek treatment.^{1,2} A twelve year review of the literature reports that 25% of all school children experience dental trauma and 33% of adults have experienced trauma to the permanent dentition with the majority of injuries occurring before age 19.³ Luxation injuries are the most common TDIs in the primary dentition, whereas crown fractures are more commonly reported for the permanent dentition.^{1,4,5} TDIs present a challenge to clinicians worldwide. Consequently, proper diagnosis treatment planning and followup are critical to assure a favorable outcome.

Guidelines, among other things, should assist dentists, other health care professionals and patients in decision making. Also, they should be credible, readily understandable and practical with the aim of delivering appropriate care as effectively and efficiently as possible.

The following guidelines by the International Association of Dental Traumatology (IADT) represent an updated set of guidelines based on the original guidelines published in 2007.⁶⁻⁸ The update was accomplished by doing a review of the current dental literature using EMBASE, MEDLINE, and PUBMED searches from 1996-2011 as well as a search of the journal of Dental Traumatology from 2000 to 2011. Search words included tooth fractures, root fractures, tooth luxation, lateral luxation and permanent teeth, intruded permanent teeth, and luxated permanent teeth.

The primary goal of these guidelines is to delineate an approach for the immediate or urgent care of TDIs. It is understood that subsequent treatment may require secondary and tertiary interventions involving specialist consultations, services and/or materials/methods not always available to the primary treating clinician.

The IADT published its first set of guidelines in 2001 and updated them in 2007.⁶⁻¹³ As with the previous guidelines, the working group included experienced investigators and clinicians from various dental specialties and general practice. This revision represents the best evidence based on the available literature and expert professional judgment. In cases where the data did not appear conclusive, recommendations are based on the consensus opinion of the working group followed by review by the members of the IADT Board of Directors. It is understood that guidelines are to be applied with evaluation of the specific clinical circumstances, clinicians' judgement and patients' characteristics, including but not limited to compliance, finances and understanding of the immediate and long-term outcomes of treatment alternatives versus non-treatment. The IADT cannot and does not guarantee favorable outcomes from strict adherence to the Guidelines, but believe that their application can maximize the chances of a favorable outcome.

Guidelines undergo periodic updates. These 2012 Guidelines will appear in three parts:

Part I: Fractures and luxations of permanent teeth

Part II: Avulsion of permanent teeth

Part III: Injuries in the primary dentition

Guidelines offer recommendations for diagnosis and treatment of specific TDIs; however, they do not provide the comprehensive nor detailed information found in textbooks, the scientific literature and most recently the Dental Trauma Guide (DTG) which can be accessed on

<http://www.dentaltraumaguide.org> . Additionally, the DTG, also available on the IADT's web page <http://www.iadt-dentaltrauma.org> provides a visual and animated documentation of treatment procedures as well as estimations of prognosis for the various TDIs.

GENERAL RECOMMENDATIONS

Clinical Examination

Detailed description of protocols, methods and documentation for clinical assessment of TDIs can be found in current textbooks.^{1,14,15}

Radiographic Examination

Several projections and angulations are routinely recommended but the clinician should decide which radiographs are required for the individual. The following are suggested:

- Periapical radiograph with a 90° horizontal angle with central beam through the tooth in question.
- Occlusal view.
- Periapical radiograph with lateral angulations from the mesial or distal aspect of the tooth in question.

Emerging imaging modalities such as cone beam computerized tomography (CBCT) provide enhanced visualization of TDIs, particularly root fractures and lateral luxations, monitoring of healing and complications. Availability is limited and its use not currently considered routine, however, specific information is available in the scientific literature.^{16,17}

Splinting: Type and Duration

Current evidence supports short-term, non-rigid splints for splinting of luxated, avulsed and root-fractured teeth. While neither the specific type of splint nor the duration of splinting are significantly related to healing outcomes (except for avulsion where the time may be of importance), it is considered best practice in order to maintain the repositioned tooth in correct position, provide patient comfort and improved function.¹⁸⁻²³

Use of Antibiotics

There is limited evidence for use of systemic antibiotics in the management of luxation injuries and no evidence that antibiotic coverage improves outcomes for root fractured teeth. Antibiotic use remains at the discretion of the clinician as TDI's are often accompanied by soft tissue and other associated injuries, which may require other surgical intervention. In addition, the patient's medical status may warrant antibiotic coverage.^{23,24}

Sensibility Tests

Sensibility testing refers to tests (cold test and/or electric pulp test) attempting to determine the condition of the pulp. At the time of injury sensibility tests frequently give no response indicating a transient lack of pulpal response. Therefore, at least two signs and symptoms are necessary to make the diagnosis of necrotic pulp. Regular followup controls are required to make a pulpal diagnosis.

Immature versus Mature Permanent Teeth

Every effort should be made to preserve pulpal vitality in the immature permanent tooth in order to ensure continuous root development. The vast majority of TDIs occur in children and teenagers where loss of a tooth has lifetime consequences. The immature permanent tooth has considerable capacity for healing after traumatic pulp exposure, luxation injury and root fractures. Pulp exposures secondary to TDIs are amenable to proven conservative pulp therapies that maintain vital pulp tissue and allow for continued root development.²⁵⁻²⁹ In addition, emerging therapies have demonstrated the ability to revascularize/regenerate vital tissue in canals of immature permanent teeth with necrotic pulps.³⁰⁻³⁵ Teeth frequently sustain a combination of several injuries. Studies have demonstrated that crown fractured teeth with or without pulp exposure and associated luxation injury experience a greater frequency of pulp necrosis.³⁶ The mature permanent tooth that sustains a severe TDI after which pulp necrosis is anticipated is amenable to preventive pulpectomy as root development is substantially completed.

Pulp Canal Obliteration

Pulp canal obliteration (PCO) occurs more frequently in teeth with open apices which have suffered a severe luxation injury. It usually indicates ongoing pulpal vitality. Extrusion, intrusion and lateral luxation injuries have high rates of PCO.^{37,38} Subluxated and crown fractured teeth also may exhibit PCO although with less frequency.³⁹ Additionally PCO is a common occurrence following root fractures.^{40,41}

Patient Instructions

Patient compliance with follow-up visits and home care contributes to better healing following a TDI. Both patients and parents of young patients should be advised regarding care of the injured tooth/teeth for optimal healing, prevention of further injury by avoidance of participation in contact sports, meticulous oral hygiene and rinsing with an antibacterial such as chlorhexidine gluconate 0.1% alcohol free for 1-2 weeks.

Additional Resources

Besides the general recommendations above, clinicians are encouraged to access the DTG, the journal Dental Traumatology, and other journals for information pertaining to treatment delay,⁴² intrusive luxations,⁴³⁻⁵² root fractures,^{24,53-57} pulpal management of fractured and luxated teeth,⁵⁸⁻⁷⁰ splinting,^{18-22,71} and antibiotics.⁷²

References

1. Andreasen JO, Andreasen FM, Andersson L. Textbook and Color Atlas of Traumatic Injuries to the Teeth. 4th ed. Oxford, England, Wiley-Blackwell: 2007.
2. Petersson EE, Andersson L, Sorensen S. Traumatic oral vs non-oral injuries. *Swed Dent J* 1997; 211(2):55-68.
3. Glendor U. Epidemiology of traumatic dental injuries – a 12 year review of the literature. *Dent Traumatol* 2008;24(6):603-11.
4. Flores MT. Traumatic injuries in the primary dentition. *Dent Traumatol* 2002; 18(6):287-98.

5. Kramer PF, Zemruski C, Ferreira SH, Fedens CA. Traumatic dental injuries in Brazilian preschool children. *Dent Traumatol* 2003; 19(6):299-303.
6. Flores MT, Andersson L, Andreasen JO, Bakland LK, Malmgren B et al. Guidelines for the management of traumatic dental injuries.1. Fractures and Luxations of permanent teeth. *Dent Traumatol* 2007; 23(2):66-71.
7. Flores MT, Andersson L, Andreasen JO, Bakland LK, Malmgren B, et al. Guidelines for the management of traumatic dental injuries.11. Avulsion of permanent teeth. *Dent Traumatol* 2007; 23(3):130-36.
8. Flores MT, Andersson L, Andreasen JO, Bakland LK, Malmgren B et al. Guidelines for the management of traumatic dental injuries.111. Primary Teeth. *Dent Traumatol* 2007; 23(4):196-202.
9. Flores MT, Andreasen JO, Bakland LK, Feiglin B, Gutmann JL et al. Guidelines for the evaluation and management of traumatic dental injuries (part 1 of the series) *Dent Traumatol* 2001;17(1):1-4.
10. Flores MT, Andreasen JO, Bakland LK, Feiglin B, Gutmann JL et al. Guidelines for the evaluation and management of traumatic dental injuries (part 2 of the series) *Dent Traumatol* 2001; 17(2):49-52.
11. Flores MT, Andreasen JO, Bakland LK, Feiglin B, Gutmann JL et al. Guidelines for the evaluation and management of traumatic dental injuries (part 3 of the series) *Dent Traumatol* 2001; 17(3):97-102.
12. Flores MT, Andreasen JO, Bakland LK, Feiglin B, Gutmann JL et al. Guidelines for the evaluation and management of traumatic dental injuries (part 4 of the series) *Dent Traumatol* 2001;17(4):145-48.
13. Flores MT, Andreasen JO, Bakland LK, Feiglin B, Gutmann JL, et al. Guidelines for the evaluation and management of traumatic dental injuries (part 5 of the series) *Dent Traumatol* 2001;17(5):193-98.
14. Andreasen JO, Bakland LK, Flores MT, Andreasen FM, Andersson L. Traumatic Dental Injuries, A Manual: 3rd ed. 2011, Wiley-Blackwell, Chichester, West Sussex.
15. Pinkham JR, Casamassino PS, Fields HW Jr., McTigue DJ, Mowak A eds. Pediatric Dentistry: 4th ed. St. Louis, MO: Elsevier Saunders: 2005.
16. Cohenca M, Simon JH, Roges R, Moragy, Malfax JM. Clinical Indications for digital imaging in dento-alveolar trauma. Part I: traumatic injuries. *Dental Traumatol* 2007; 23:95-104.
17. Cohenca M, Simon JH, Roges R, Moragy, Malfax JM. Clinical Indications for digital imaging in dento-alveolar trauma. Part 2: root resorption. *Dental Traumatol* 2007; 23(2):105-113
18. Kahler B, Heithersay GS. An evidence-based appraisal of splinting luxated, avulsed and root-fractured teeth. *Dental Traumatol* 2008; 24:2-10.
19. Hinckfuss S, Messer LB. Splinting duration and periodontal outcomes for replanted avulsed teeth, a systematic review. *Dent Traumatol* 2009; 25(2):150-7.
20. Andreasen JO, Bakland LK, Andreasen FM. Traumatic intrusion of permanent teeth. Part 3. A clinical study of the effect of treatment variables such as treatment delay, method of repositioning, type of splint, length of splinting and antibiotics on 140 teeth. *Dent Traumatol* 2006; 22(2):90-111.
21. Oikarinen, K. Tooth Splinting – a review of the literature and consideration of the versatility of a wire-composite splint. *Endod Dent Traumatol* 1990; 6(6); 237-50.
22. VonArx T, Fillipi A, Lussi A. Comparison of a new dental trauma splint device (TTS) with three commonly used splinting techniques. *Dent Traumatol* 2001; 17(6):266-74.


23. Andreasen JO, Andreasen FM, Mejaré I, Cvek M. Healing of 400 intra-alveolar root fractures 2. Effect of treatment factors such as treatment delay, repositioning, splinting type and period and antibiotics. *Dent Traumatol* 2004; 20(4):203-11.
24. Hinckfuss SE, Messer LB. An evidence-based assessment of the clinical guidelines for replanted avulsed teeth. Part II: prescription of systemic antibiotics. *Dent Traumatol* 2009;25(2):158-164.
25. Cvek M. A clinical report on partial pulpotomy and capping with calcium hydroxide in permanent incisors with complicated crown fractures. *J Endod* 1978; 4(8):232-7.
26. Fuks AB, Bielak S, Chosak A. Clinical and radiographic assessment of direct pulp capping and pulpotomy in young permanent teeth. *Pediatr Dent* 1982; 4(3):240-44.
27. Cvek M, Mejára I, Andreasen JO. Conservative endodontic treatment in the middle or apical part of the root. *Dent Traumatol* 2004; 20(5):261-69.
28. Olsburgh S, Jacoby T, Krejei I. Crown fractures in the permanent dentition: pulpal and restorative considerations. *Dental Traumatol* 2002; 18(3):103-15.
29. Witherspoon DE, Vital pulp therapy with new materials: new directions and treatment perspectives – permanent teeth. *Pediatr Dent* 2008; 30(3):220-4.
30. Huang GT. A paradigm shift in endodontic management of immature teeth: conservation of stem cells for regeneration. *J Dent* 2008 Jun; 36(6):379-86. Epub 2008 Apr 16.
31. Chueh LH, Ho YC, Kuo TC, Lai WH, Chen YH, Chiang CP. Regenerative endodontic treatment for necrotic immature permanent teeth. *J Endod* 2009; 35(2):160-4. Epub 2008 Dec 12.
32. Bose R, Nummikoski P, Hargreaves K. A retrospective evaluation of radiographic outcomes in immature teeth with necrotic root canal systems treated with regenerative endodontic procedures. *J Endod* 2009 Oct; 35(10):1343-9. Epub 2009 Aug 15.
33. Thibodeau B, Trope M. Pulp revascularization of a necrotic infected immature permanent tooth: case report and review of the literature. *Pediatr Dent* 2007 Jan-Feb; 29(1):47-50.
34. Trope M. Treatment of the immature tooth with a non-vital pulp and apical periodontitis. *Dent Clin North Am.* 2010 Apr; 54(2):313-24.
35. Jung IY, Lee SJ, Hargreaves KM. Biologically based treatment of immature permanent teeth with pulpal necrosis: a case series. *J Endod* 2008 Jul;34(7):876-87. Epub 2008 May 16.
36. Robertson A, Andreasen FM, Andreasen JO, Noren JG. Long-term prognosis of crown-fractured permanent incisors. The effect of stage of root development and associated luxation injuries. *Int J Pediatr Dent* 2000; 103:191-9.
37. Holcomb JB, Gregory WB Jr. Calcific metamorphosis of the pulp; its incidence and treatment. *Oral Surg Oral Med Oral Pathol* 1967; 24(6):825-30.
38. Neto JJ, Gondim JO, deCarvalho FM, Giro EM. Longitudinal clinical and radiographic evaluations of severely intruded permanent incisors in a pediatric population. *Dent Traumatol* 2009; 25(5):510-24.
39. Robertson A. A retrospective evaluation of patients with uncomplicated crown fractures and luxation injuries. *Endod Dent Traumatol* 1998; 14:245-56.
40. Amir FA, Gutmann JL, Witherspoon DE. Calcific metamorphosis: a challenge in endodontic diagnosis and treatment. *Quintessence Int* 2001; 32:447-55.
41. Andreasen FM, Andreasen JO, Bayer T. Prognosis of root fractured permanent incisors; prediction of healing modalities. *Endod Dent Traumatol* 1989; 5(1):11-22.


42. Andreasen JO, Andreasen FM, Skeie A, Hjørting-Hansen E, Schwartz O. Effect of treatment delay upon pulp and periodontal healing of traumatic dental injuries – a review article. *Dent Traumatol* 2002; 18(3):116-28.
43. Kenny DJ, Barrett EJ, Casas MJ. Avulsions and Intrusions: the controversial displacement injuries. *J Can Dent Assoc* 2003;69(5):308-13.
44. Stewart C, Dawson M, Phillips J, Shafi I, Kinirons M, Welburg R. A study of the management of 55 traumatically intruded permanent incisor teeth in children. *Eur Arch Paediatr Dent* 2009; 10(1):25-8.
45. Albadri S, Zaitoun H, Kinirous MJ. UK National Clinical Guidelines in Paediatric Dentistry: Treatment of traumatically intruded permanent incisor teeth in children. *Int Ass Paed Dent* 2010; 20(suppl.1):1-2.
46. Andreasen JO, Bakland LK, Matras RC, Andreasen FM. Traumatic intrusion of permanent teeth. Part 1. An epidemiological study of 216 intruded permanent teeth. *Dent Traumatol* 2006; 22(2):83-9.
47. Andreasen JO, Bakland LK, Andreasen FM. Traumatic intrusion of permanent teeth. Part 2. A clinical study of the effect of preinjury and injury factors such as sex, age, stage of root development, tooth location and extent of injury including number of intruded teeth on 140 intruded permanent teeth. *Dent Traumatol* 2006; 22(2):90-8.
48. Andreasen JO, Bakland LK, Andreasen FM. Traumatic intrusion of permanent teeth. Part 3. A clinical study of the effect treatment variables such as treatment delay, method of repositioning, type of splint, length of splinting and antibiotics on 140 teeth. *Dent Traumatol* 2006; 22(2):99-111.
49. Wiggen TI, Agnalt R, Jacobsen I. Intrusive luxation of permanent incisors in Norwegians aged 6-17 years: a retrospective study of treatment and outcome. *Dent Traumatol* 2008; 24(6):612-18.
50. Ebeleseder KA, Santler G, Glockner K, Huller H, Perfl C, Quehenberger F. An analysis of 58 traumatically intruded and surgically extruded permanent teeth. *Dent Traumatol* 2000; 16(1):34-9.
51. Humphrey JM, Kenny DJ, Barrett EJ. Clinical outcomes for permanent incisor luxations in a pediatric population.I. Intrusions. *Dent Traumatol* 2003; 19(5):266-73.
52. Al Badri S, Kinirons M, Cole B, Welbury R. Factors affecting resorption in traumatically intruded permanent incisors in children. *Dent Traumatol* 2002; 18(2):73-6.
53. Andreasen JO, Andreasen FM, Mejare I, Cvek M. Healing of 400 intra-alveolar root fractures.I. Effect of pre-injury and injury factors such as sex, age, stage of root development, fracture type, location of fracture and severity of dislocation. *Dent Traumatol* 2004; 20(4):192-202.
54. Cvek M, Andreasen JO, Borum MK. Healing of 208 intra-alveolar root fractures in patients aged 7-17 years. *Dent Traumatol* 2001; 17(2):53-62.
55. Welbury RR, Kinirons MJ, Day P, Humphreys K, Gregg TA. Outcomes for root-fractured permanent incisors; a retrospective study. *Pediatr Dent* 2002; 24(2):98-102
56. Cvek M, Mejare I, Andreasen JO. Healing and prognosis of teeth with intra-alveolar fractures involving the cervical part of the root. *Dent Traumatol* 2002; 18(2):57-65.
57. Cvek M, Tsilingaridis G, Andreasen JO. Survival of 534 incisors after intra-alveolar root fracture in 7-17 years. *Dent Traumatol* 2008; 24(4):379-87.
58. Robertson A. A retrospective evaluation of patients with uncomplicated crown fractures and luxation injuries. *Endod Traumatol* 1998; 14(6):245-56.
59. Farsi N, Alamoudi N, Balto K, Al Muskagy A. Clinical assessment of mineral trioxide aggregate (MTA) as direct pulp capping in young permanent teeth. *J Clin Pediatr Dent* 2006; 31(2):72-76.

60. Moule AJ, Moule CA. The endodontic management of traumatized anterior teeth: a review. *Aust Dent J Endo Supplement* 2007; 52(1 Suppl):S122-37.
61. Bakland LK. Revisiting traumatic pulpal exposure: Materials, management principles and techniques. *Dent Clin N Am* 2009; 53(4):661-73.
62. Cavalleri G, Zerman N. Traumatic crown fractures in permanent incisors with immature roots: a follow-up study. *Endod Dent Traumatol* 1995;11(6):294-96.
63. Ferrazzini Pozzi EC, von Arx T. Pulp and periodontal healing of laterally luxated permanent teeth; results after 4 years. *Dent Traumatol* 2008;24(6):658-62.
64. Nikoui M, Kenny DJ, Barrett EJ. Clinical outcomes for permanent incisor luxation in a pediatric population.III. Lateral luxations. *Dent Traumatol* 2003;19(5):280-5.
65. Jackson NG, Waterhouse PJ, Maguire A. Factors affecting treatment outcomes following complicated crown fractures managed in primary and secondary care. *Dent Traumatol* 2006;22(4):179-85.
66. Trope M: Treatment of the immature tooth with non-vital pulp and apical periodontics. *Dent Clin N Am* 2010;54(2):313-24.
67. About I, Murray PE, Franquin JC, Remusat M, and Smith AJ. The effect of cavity restoration variables on odontoblast cell numbers and dental repair. *J Dent* 2001;29(2):109-17.
68. Murray PE, Smith AJ, Windsor LJ, and Mjor IA. Remaining dentine thickness and human pulp responses. *Int Endod J* 2003;36(1):33-43.
69. Subay RK, Demirci M. Pulp tissue reactions to a dentin bonding agent as a direct capping agent. *J Endod* 2005;31(3):201-04.
70. Bogen G, Kim JS, Bakland LK. Direct pulp capping with mineral trioxide aggregate: an observational study. *J Am Dent Assoc* 2008;139(3):305-15.
71. Berthold C, Thaler A, Petschelt A. Rigidity of commonly used dental trauma splints. *Dent Traumatol* 2009;25(93):248-55.
72. Andreasen JO, Storgaard Jensen S, Sae-Lim V. The role of antibiotics in preventing healing complications after traumatic dental injuries: a literature review. *Endod Topics* 2006;14:80-92

PERMANENT TEETH


1. Treatment guidelines for fractures of teeth and alveolar bone


1. Treatment guidelines for fractures of teeth and alveolar bone				Followup Procedures for fractures of teeth and alveolar bone ⁺	Favorable and Unfavorable outcomes include some, but not necessarily all, of the following:	
INFRACTION	Clinical findings	Radiographic findings	Treatment	Follow-Up	Favorable Outcome	Unfavorable Outcome
	<ul style="list-style-type: none"> • An incomplete fracture (crack) of the enamel without loss of tooth structure. • Not tender. If tenderness is observed evaluate the tooth for a possible luxation injury or a root fracture. 	<ul style="list-style-type: none"> • No radiographic abnormalities. • Radiographs recommended: a periapical view. Additional radiographs are indicated if other signs or symptoms are present. 	<ul style="list-style-type: none"> • In case of marked infractions, etching and sealing with resin to prevent discoloration of the infraction lines. Otherwise, no treatment is necessary. 	<ul style="list-style-type: none"> • No follow-up is generally needed for infraction injuries unless they are associated with a luxation injury or other fracture types. 	<ul style="list-style-type: none"> • Asymptomatic • Positive response to pulp testing. • Continuing root development in immature teeth. 	<ul style="list-style-type: none"> • Symptomatic • Negative response to pulp testing. • Signs of apical periodontitis. • No continuing root development in immature teeth. • Endodontic therapy appropriate for stage of root development is indicated.

ENAMEL FRACTURE	Clinical findings	Radiographic findings	Treatment	Followup	Favorable Outcome	Unfavorable Outcome
	<ul style="list-style-type: none"> • A complete fracture of the enamel. • Loss of enamel. No visible sign of exposed dentin. • Not tender. If tenderness is observed evaluate the tooth for a possible luxation or root fracture injury. • Normal mobility. • Sensibility pulp test usually positive. 	<ul style="list-style-type: none"> • Enamel loss is visible. • Radiographs recommended: periapical, occlusal and eccentric exposures. These are recommended in order to rule out the possible presence of a root fracture or a luxation injury. • Radiograph of lip or cheek to search for tooth fragments or foreign materials. 	<ul style="list-style-type: none"> • If the tooth fragment is available, it can be bonded to the tooth. • Contouring or restoration with composite resin depending on the extent and location of the fracture. 	6-8 weeks C ⁺⁺ 1 year C ⁺⁺	<ul style="list-style-type: none"> • Asymptomatic • Positive response to pulp testing. • Continuing root development in immature teeth. • Continue to next evaluation. 	<ul style="list-style-type: none"> • Symptomatic • Negative response to pulp testing. • Signs of apical periodontitis • No continuing root development in immature teeth. • Endodontic therapy appropriate for stage of root development is indicated.

⁺ = for crown fractured teeth with concomitant luxation injury, use the luxation followup schedule.


C⁺⁺ = clinical and radiographic examination.

				Follow-Up Procedures for fractures of teeth and alveolar bone ⁺	Favorable and Unfavorable outcomes include some, but not necessarily all, of the following:	
ENAMEL-DENTIN-FRACTURE	Clinical findings	Radiographic findings	Treatment	Follow-Up	Favorable Outcome	Unfavorable Outcome
	<ul style="list-style-type: none"> • A fracture confined to enamel and dentin with loss of tooth structure, but not exposing the pulp. • Percussion test: not tender. If tenderness is observed, evaluate the tooth for possible luxation or root fracture injury. • Normal mobility. • Sensibility pulp test usually positive. 	<ul style="list-style-type: none"> • Enamel-dentin loss is visible. • Radiographs recommended: periapical, occlusal and eccentric exposure to rule out tooth displacement or possible presence of root fracture. • Radiograph of lip or cheek lacerations to search for tooth fragments or foreign materials. 	<ul style="list-style-type: none"> • If a tooth fragment is available, it can be bonded to the tooth. Otherwise perform a <u>provisional treatment</u> by covering the exposed dentin with glass-ionomer or a more permanent restoration using a bonding agent and composite resin, or other accepted dental restorative materials • If the exposed dentin is within 0.5mm of the pulp (pink, no bleeding) place calcium hydroxide base and cover with a material such as a glass ionomer. 	6-8 weeks C ⁺⁺ 1 year C ⁺⁺	<ul style="list-style-type: none"> • Asymptomatic • Positive response to pulp testing. • Continuing root development in immature teeth • Continue to next evaluation 	<ul style="list-style-type: none"> • Symptomatic • Negative response to pulp testing. • Signs of apical periodontitis. • No continuing root development in immature teeth. • Endodontic therapy appropriate for stage of root development is indicated.

ENAMEL-DENTIN-PULP FRACTURE	Clinical findings	Radiographic findings	Treatment		Favorable Outcome	Unfavorable Outcome
	<ul style="list-style-type: none"> • A fracture involving enamel and dentin with loss of tooth structure and exposure of the pulp. • Normal mobility • Percussion test: not tender. If tenderness is observed, evaluate for possible luxation or root fracture injury. • Exposed pulp sensitive to stimuli. 	<ul style="list-style-type: none"> • Enamel – dentin loss visible. • Radiographs recommended: periapical, occlusal and eccentric exposures, to rule out tooth displacement or possible presence of root fracture. • Radiograph of lip or cheek lacerations to search for tooth fragments or foreign materials. 	<ul style="list-style-type: none"> • In young patients with immature, still developing teeth, it is advantageous to preserve pulp vitality by pulp capping or partial pulpotomy. Also, this treatment is the choice in young patients with completely formed teeth. • Calcium hydroxide is a suitable material to be placed on the pulp wound in such procedures. • In patients with mature apical development, root canal treatment is usually the treatment of choice, although pulp capping or partial pulpotomy also may be selected. • If tooth fragment is available, it can be bonded to the tooth. • Future treatment for the fractured crown may be restoration with other accepted dental restorative materials. 	6-8 weeks C ⁺⁺ 1 year C ⁺⁺	<ul style="list-style-type: none"> • Asymptomatic. • Positive response to pulp testing. • Continuing root development in immature teeth. • Continue to next evaluation. 	<ul style="list-style-type: none"> • Symptomatic. • Negative response to pulp testing. • Signs of apical periodontitis. • No continuing root development in immature teeth. • Endodontic therapy appropriate for stage of root development is indicated.


⁺ = for crown fractured teeth with concomitant luxation injury, use the luxation followup schedule

C⁺⁺ = clinical and radiographic examination.

				Follow-Up Procedures for fractures of teeth and alveolar bone +	Favorable and Unfavorable outcomes include some, but not necessarily all, of the following:	
CROWN-ROOT FRACTURE WITHOUT PULP EXPOSURE	Clinical findings	Radiographic findings	Treatment	Follow-Up	Favorable Outcome	Unfavorable Outcome
 <p>A diagram showing a cross-section of a tooth with a fracture line extending from the crown down to the root, just above the gingival margin. The pulp chamber is visible and not exposed.</p>	<ul style="list-style-type: none"> • A fracture involving enamel, dentin and cementum with loss of tooth structure, but not exposing the pulp. • Crown fracture extending below gingival margin. • Percussion test: Tender. • Coronal fragment mobile. • Sensibility pulp test usually positive for apical fragment. 	<ul style="list-style-type: none"> • Apical extension of fracture usually not visible. • Radiographs recommended: periapical, occlusal and eccentric exposures. They are recommended in order to detect fracture lines in the root. 	<p>Emergency treatment</p> <ul style="list-style-type: none"> • As an emergency treatment a temporary stabilization of the loose segment to adjacent teeth can be performed until a definitive treatment plan is made. <p>Non-Emergency Treatment Alternatives</p> <p>Fragment removal only</p> <ul style="list-style-type: none"> • Removal of the coronal crown-root fragment and subsequent restoration of the apical fragment exposed above the gingival level. <p>Fragment removal and gingivectomy (sometimes ostectomy)</p> <ul style="list-style-type: none"> • Removal of the coronal crown-root segment with subsequent endodontic treatment and restoration with a post-retained crown. This procedure should be preceded by a gingivectomy, and sometimes ostectomy with osteoplasty. <p>Orthodontic extrusion of apical fragment</p> <ul style="list-style-type: none"> • Removal of the coronal segment with subsequent endodontic treatment and orthodontic extrusion of the remaining root with sufficient length after extrusion to support a post-retained crown. <p>Surgical extrusion</p> <ul style="list-style-type: none"> • Removal of the mobile fractured fragment with subsequent surgical repositioning of the root in a more coronal position. <p>Root submergence</p> <ul style="list-style-type: none"> • Implant solution is planned. <p>Extraction</p> <ul style="list-style-type: none"> • Extraction with immediate or delayed implant-retained crown restoration or a conventional bridge. Extraction is inevitable in crown-root fractures with a severe apical extension, the extreme being a vertical fracture. 	<p>6-8 weeks C⁺⁺ 1 year C⁺⁺</p>	<ul style="list-style-type: none"> • Asymptomatic • Positive response to pulp testing. • Continuing root development in immature teeth • Continue to next evaluation 	<ul style="list-style-type: none"> • Symptomatic • Negative response to pulp testing. • Signs of apical periodontitis. • No continuing root development in immature teeth. • Endodontic therapy appropriate for stage of root development is indicated.



+ = for crown fractured teeth with concomitant luxation injury, use the luxation followup schedule.

C++ = clinical and radiographic examination

				Follow-Up Procedures for fractures of teeth and alveolar bone +	Favorable and Unfavorable outcomes include some, but not necessarily all, of the following:	
CROWN-ROOT FRACTURE WITH PULP EXPOSURE	Clinical findings	Radiographic findings	Treatment	Follow-Up	Favorable Outcome	Unfavorable Outcome
	<ul style="list-style-type: none"> • A fracture involving enamel, dentin, and cementum and exposing the pulp. • Percussion test: tender. • Coronal fragment mobile. 	<ul style="list-style-type: none"> • Apical extension of fracture usually not visible. • Radiographs recommended: periapical and occlusal exposure. 	<p>Emergency treatment</p> <ul style="list-style-type: none"> • As an emergency treatment a temporary stabilization of the loose segment to adjacent teeth. • In patients with open apices, it is advantageous to preserve pulp vitality by a partial pulpotomy. This treatment is also the choice in young patients with completely formed teeth. Calcium hydroxide compounds are suitable pulp capping materials. In patients with mature apical development, root canal treatment can be the treatment of choice. <p>Non-Emergency Treatment Alternatives</p> <ul style="list-style-type: none"> • Fragment removal and gingivectomy (sometimes ostectomy) Removal of the coronal fragment with subsequent endodontic treatment and restoration with a post-retained crown. This procedure should be preceded by a gingivectomy and sometimes ostectomy with osteoplasty. This treatment option is only indicated in crown-root fractures with palatal subgingival extension. • Orthodontic extrusion of apical fragment Removal of the coronal segment with subsequent endodontic treatment and orthodontic extrusion of the remaining root with sufficient length after extrusion to support a post-retained crown. • Surgical extrusion Removal of the mobile fractured fragment with subsequent surgical repositioning of the root in a more coronal position. • Root submergence If an implant solution is planned, the root fragment may be left in situ. • Extraction Extraction with immediate or delayed implant-retained crown restoration or a conventional bridge. Extraction is inevitable in very deep crown-root fractures, the extreme being a vertical fracture 	<p>6-8 weeks C⁺⁺ 1 year C⁺⁺</p>	<ul style="list-style-type: none"> • Asymptomatic • Positive response to pulp testing. • Continuing root development in immature teeth • Continue to next evaluation 	<ul style="list-style-type: none"> • Symptomatic • Negative response to pulp testing. • Signs of apical periodontitis. • No continuing root development in immature teeth. • Endodontic therapy appropriate for stage of root development is indicated.

⁺= for crown fractured teeth with concomitant luxation injury, use the luxation followup schedule

C⁺⁺ = clinical and radiographic examination;




				Follow-Up Procedures for fractures of teeth and alveolar bone	Favorable and Unfavorable outcomes include some, but not necessarily all, of the following: ⁺⁺	
ROOT FRACTURE	Clinical findings	Radiographic findings	Treatment		Favorable Outcome	Unfavorable Outcome
	<ul style="list-style-type: none"> • The coronal segment may be mobile and may be displaced. • The tooth may be tender to percussion. • Bleeding from the gingival sulcus may be noted. • Sensibility testing may give negative results initially, indicating transient or permanent neural damage. • Monitoring the status of the pulp is recommended. • Transient crown discoloration (red or grey) may occur. 	<ul style="list-style-type: none"> • The fracture involves the root of the tooth and is in a horizontal or oblique plane. • Fractures that are in the horizontal plane can usually be detected in the regular periapical 90° angle film with the central beam through the tooth. This is usually the case with fractures in the cervical third of the root. • If the plane of fracture is more oblique which is common with apical third fractures, an occlusal view or radiographs with varying horizontal angles are more likely to demonstrate the fracture including those located in the middle third. 	<ul style="list-style-type: none"> • Reposition, if displaced, the coronal segment of the tooth as soon as possible. • Check position radiographically. • Stabilize the tooth with a flexible splint for 4 weeks. If the root fracture is near the cervical area of the tooth, stabilization is beneficial for a longer period of time (up to 4 months). • It is advisable to monitor healing for at least one year to determine pulpal status. • If pulp necrosis develops, root canal treatment of the coronal tooth segment to the fracture line is indicated to preserve the tooth. 	4 Weeks S ⁺ , C ⁺⁺ 6-8 Weeks C ⁺⁺ 4 Months S ⁺⁺⁺ , C ⁺⁺ 6 Months C ⁺⁺ 1 Year C ⁺⁺ 5 Years C ⁺⁺	<ul style="list-style-type: none"> • Positive response to pulp testing (false negative possible up to 3 months). • Signs of repair between fractured segments. • Continue to next evaluation. 	<ul style="list-style-type: none"> • Symptomatic • Negative response to pulp testing (false negative possible up to 3 months). • Extrusion of the coronal segment. • Radiolucency at the fracture line. • Clinical signs of periodontitis or abscess associated with the fracture line. • Endodontic therapy appropriate for stage of root development is indicated.
ALVEOLAR FRACTURE	Clinical findings	Radiographic findings	Treatment	Follow-Up	Favorable Outcome	Unfavorable Outcome
	<ul style="list-style-type: none"> • The fracture involves the alveolar bone and may extend to adjacent bone. • Segment mobility and dislocation with several teeth moving together are common findings. • An occlusal change due to misalignment of the fractured alveolar segment is often noted. • Sensibility testing may or may not be positive. 	<ul style="list-style-type: none"> • Fracture lines may be located at any level, from the marginal bone to the root apex. • In addition to the 3 angulations and occlusal film, additional views such as a panoramic radiograph can be helpful in determining the course and position of the fracture lines. 	<ul style="list-style-type: none"> • Reposition any displaced segment and then splint. • Suture gingival laceration if present. • Stabilize the segment for 4 weeks. 	4 Weeks S ⁺ , C ⁺⁺ 6-8 Weeks C ⁺⁺ 4 Months C ⁺⁺ 6 Months C ⁺⁺ 1 Year C ⁺⁺ 5 Years C ⁺⁺	<ul style="list-style-type: none"> • Positive response to pulp testing (false negative possible up to 3 months). • No signs of apical periodontitis. • Continue to next evaluation. 	<ul style="list-style-type: none"> • Symptomatic • Negative response to pulp testing (false negative possible up to 3 months). • Signs of apical periodontitis or external inflammatory root resorption. • Endodontic therapy appropriate for stage of root development is indicated.

S⁺=splint removal; S⁺⁺=splint removal in cervical third fractures.

C⁺⁺ = clinical and radiographic examination.

++=Whenever there is evidence of external inflammatory root resorption, root canal therapy should be initiated immediately, with the use of calcium hydroxide as an intra-canal medication.


2. Treatment Guidelines for Luxation Injuries


				Follow-Up Procedures for luxated permanent teeth	Favorable and Unfavorable outcomes include some, but not necessarily all, of the following: ⁺⁺	
CONCUSSION	Clinical findings	Radiographic findings	Treatment		Favorable Outcome	Unfavorable Outcome
	<ul style="list-style-type: none"> The tooth is tender to touch or tapping; it has not been displaced and does not have increased mobility. Sensibility tests are likely to give positive results. 	<ul style="list-style-type: none"> No radiographic abnormalities 	<ul style="list-style-type: none"> No treatment is needed. Monitor pulpal condition for at least one year. 	4 Weeks C ⁺⁺ 6-8 Weeks C ⁺⁺ 1 Year C ⁺⁺	<ul style="list-style-type: none"> Asymptomatic Positive response to pulp testing False negative possible up to 3 months. Continuing root development in immature teeth Intact lamina dura 	<ul style="list-style-type: none"> Symptomatic Negative response to pulp testing False negative possible up to 3 months No continuing root development in immature teeth, signs of apical periodontitis. Endodontic therapy appropriate for stage of root development is indicated.
SUBLUXATION	Clinical findings	Radiographic findings	Treatment	Follow-Up	Favorable Outcome	Unfavorable Outcome
	<ul style="list-style-type: none"> The tooth is tender to touch or tapping and has increased mobility; it has not been displaced. Bleeding from gingival crevice may be noted. Sensibility testing may be negative initially indicating transient pulpal damage. Monitor pulpal response until a definitive pulpal diagnosis can be made. 	<ul style="list-style-type: none"> Radiographic abnormalities are usually not found. 	<ul style="list-style-type: none"> Normally no treatment is needed, however a flexible splint to stabilize the tooth for patient comfort can be used for up to 2 weeks. 	2 Weeks S ⁺ , C ⁺⁺ 4 Weeks C ⁺⁺ 6-8 Weeks C ⁺⁺ 6 Months C ⁺⁺ 1 Year C ⁺⁺	<ul style="list-style-type: none"> Asymptomatic Positive response to pulp testing False negative possible up to 3 months. Continuing root development in immature teeth Intact lamina dura 	<ul style="list-style-type: none"> Symptomatic Negative response to pulp testing False negative possible up to 3 months External inflammatory resorption. No continuing root development in immature teeth, signs of apical periodontitis. Endodontic therapy appropriate for stage of root development is indicated.
EXTRUSIVE LUXATION	Clinical Findings	Radiographic findings	Treatment	Follow-Up	Favorable Outcome	Unfavorable Outcome
	<ul style="list-style-type: none"> The tooth appears elongated and is excessively mobile. Sensibility tests will likely give negative results. 	<ul style="list-style-type: none"> Increased periodontal ligament space apically. 	<ul style="list-style-type: none"> Reposition the tooth by gently re-inserting it into the tooth socket. Stabilize the tooth for 2 weeks using a flexible splint. In mature teeth where pulp necrosis is anticipated or if several signs and symptoms indicate that the pulp of mature or immature teeth became necrotic, root canal treatment is indicated. 	2 Weeks S ⁺ , C ⁺⁺ 4 Weeks C ⁺⁺ 6-8 Weeks C ⁺⁺ 6 Months C ⁺⁺ 1 Year C ⁺⁺ Yearly 5 years C ⁺⁺	<ul style="list-style-type: none"> Asymptomatic Clinical and radiographic signs of normal or healed periodontium. Positive response to pulp testing (false negative possible up to 3 months). Marginal bone height corresponds to that seen radiographically after repositioning. Continuing root development in immature teeth. 	<ul style="list-style-type: none"> Symptoms and radiographic sign consistent with apical periodontitis. Negative response to pulp testing (false negative possible up to 3 months). If breakdown of marginal bone, splint for an additional 3-4 weeks. External inflammatory root resorption. Endodontic therapy appropriate for stage of root development is indicated.

S⁺=splint removal;

C⁺⁺ = clinical and radiographic examination.

++=Whenever there is evidence of external inflammatory root resorption, root canal therapy should be initiated immediately, with the use of calcium hydroxide as an intra-canal medication.

				Follow-Up Procedures for luxated permanent teeth	Favorable and Unfavorable outcomes include some, but not necessarily all, of the following: ⁺⁺	
LATERAL LUXATION	Clinical findings	Radiographic findings	Treatment		Favorable Outcome	Unfavorable Outcome
	<ul style="list-style-type: none"> The tooth is displaced, usually in a palatal/lingual or labial direction. It will be immobile and percussion usually gives a high, metallic (ankylotic) sound. Fracture of the alveolar process present. Sensibility tests will likely give negative results 	<ul style="list-style-type: none"> The widened periodontal ligament space is best seen on eccentric or occlusal exposures. 	<ul style="list-style-type: none"> Reposition the tooth digitally or with forceps to disengage it from its bony lock and gently reposition it into its original location. Stabilize the tooth for 4 weeks using a flexible splint. Monitor the pulpal condition. If the pulp becomes necrotic, root canal treatment is indicated to prevent root resorption. 	2 Weeks S ⁺ , C ⁺⁺ 4 Weeks C ⁺⁺ 6-8 Weeks C ⁺⁺ 6 Months C ⁺⁺ 1 Year C ⁺⁺ Yearly for 5 years C ⁺⁺	<ul style="list-style-type: none"> Asymptomatic Clinical and radiographic signs of normal or healed periodontium. Positive response to pulp testing (false negative possible up to 3 months). Marginal bone height corresponds to that seen radiographically after repositioning. Continuing root development in immature teeth 	<ul style="list-style-type: none"> Symptoms and radiographic signs consistent with apical periodontitis. Negative response to pulp testing (false negative possible up to 3 months). If breakdown of marginal bone, splint for an additional 3-4 weeks. External inflammatory root resorption or replacement resorption Endodontic therapy appropriate for stage of root development is indicated.

				Follow-Up	Favorable Outcome	Unfavorable
INTRUSIVE LUXATION	Clinical findings	Radiographic findings	Treatment			
	<ul style="list-style-type: none"> The tooth is displaced axially into the alveolar bone. It is immobile and percussion may give a high, metallic (ankylotic) sound. Sensibility tests will likely give negative results. 	<ul style="list-style-type: none"> The periodontal ligament space may be absent from all or part of the root. The cemento-enamel junction is located more apically in the intruded tooth than in adjacent non-injured teeth, at times even apical to the marginal bone level. 	<p><u>Teeth with incomplete root formation</u></p> <ul style="list-style-type: none"> Allow eruption without intervention If no movement within few weeks, initiate orthodontic repositioning. If tooth is intruded more than 7mm, reposition surgically or orthodontically. <p><u>Teeth with complete root formation:</u></p> <ul style="list-style-type: none"> Allow eruption without intervention if tooth intruded less than 3mm. If no movement after 2-4 weeks, reposition surgically or orthodontically before ankylosis can develop. If tooth is intruded beyond 7mm, reposition surgically. The pulp will likely become necrotic in teeth with complete root formation root canal therapy using a temporary filling with calcium hydroxide is recommended and treatment should begin 2-3 weeks after surgery. Once an intruded tooth has been repositioned surgically or orthodontically, stabilize with a flexible splint for 4-8 weeks. 	2 Weeks S ⁺ , C ⁺⁺ 4 Weeks C ⁺⁺ 6-8 Weeks C ⁺⁺ 6 Months C ⁺⁺ 1 Year C ⁺⁺ Yearly for 5 years C ⁺⁺	<ul style="list-style-type: none"> Tooth in place or erupting. Intact lamina dura No signs of resorption. Continuing root development in immature teeth. 	<ul style="list-style-type: none"> Tooth locked in place/ankylotic tone to percussion. Radiographic signs of apical periodontitis External inflammatory root resorption or replacement resorption. Endodontic therapy appropriate for stage of root development is indicated.

S⁺=splint removal;

C⁺⁺ = clinical and radiographic examination.

++=Whenever there is evidence of external inflammatory root resorption, root canal therapy should be initiated immediately, with the use of calcium hydroxide as an intra-canal medication.

TASK FORCES

FRACTURES AND LUXATIONS:

Dr. Jens Andreasen, Denmark

Dr. Anthony DiAngelis, USA

Dr. Kurt Ebeleseder, Austria

Dr. David Kenny, Canada

Dr. Martin Trope, USA

Dr. Asgeir Sigurdsson, Iceland